

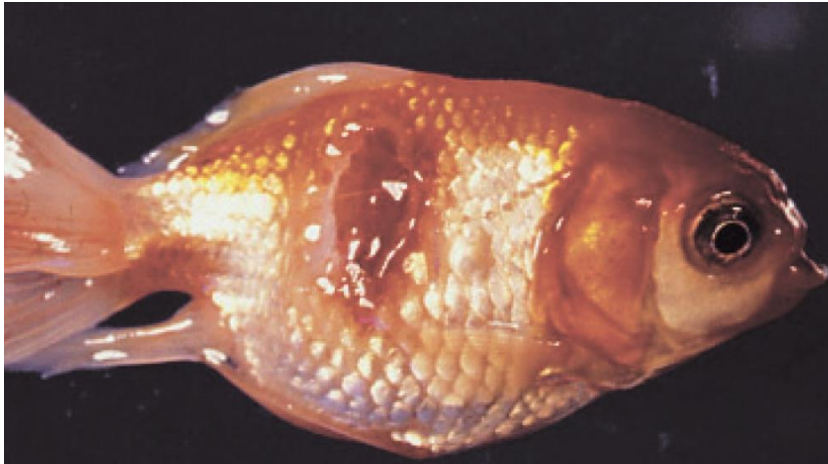

## Infection with *Aeromonas salmonicida*— atypical strains

Also known as infection with atypical strains of *Aeromonas salmonicida*, marine aeromonad disease of salmonids (MAS), goldfish ulcer disease, carp erythrodermatitis and ulcer disease of flounder, eel and salmon

From *Aquatic animal diseases significant to Australia: identification field guide*, 5th edition

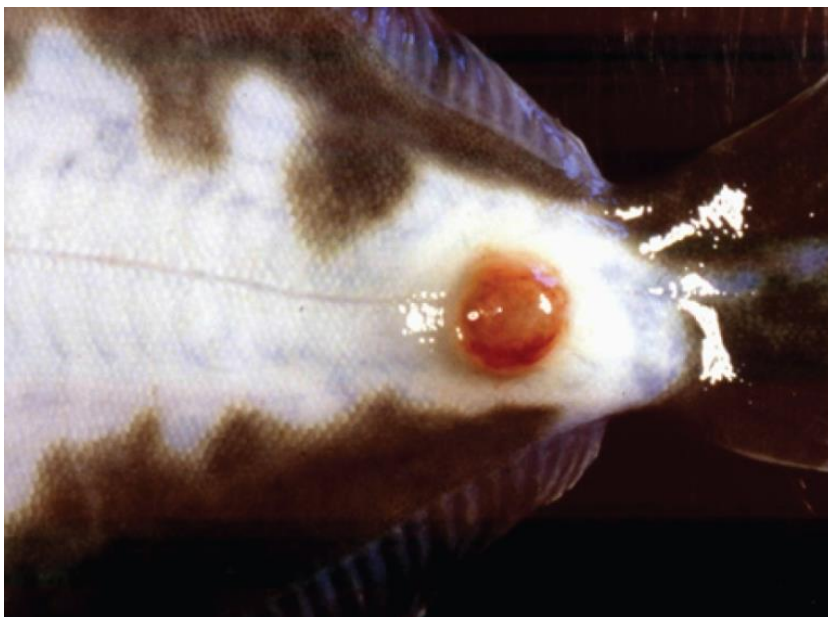Figure 1 Goldfish ulcer disease in goldfish (*Carassius auratus*)



Note: Characteristic ulcers on the body.

Source: J Carson

Figure 2 Greenback flounder (*Rhombosolea tapirina*) infected with greenback flounder strain of *Aeromonas salmonicida*



Note: Ulcer on ventral side of body.

Source: J Carson.

**Figure 3 Infection with atypical *Aeromonas salmonicida* in silver perch (*Bidyanus bidyanus*)**



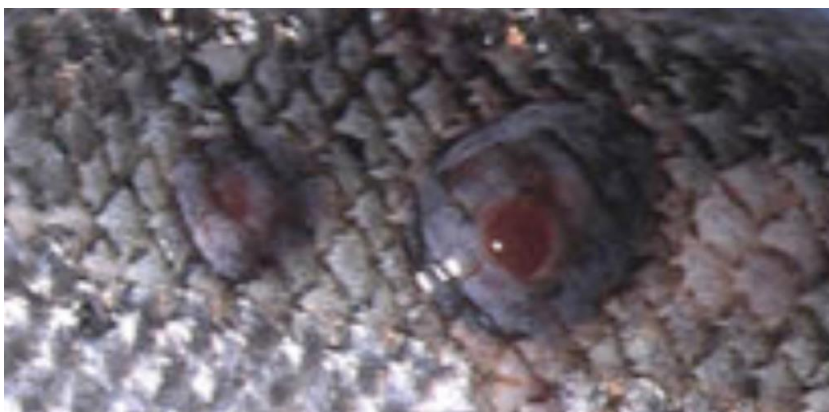Note: Ulcers on body.  
Source: M Landos

**Figure 4 Infection with *Aeromonas salmonicida* biovar Acheron in Atlantic salmon (*Salmo salar*)**



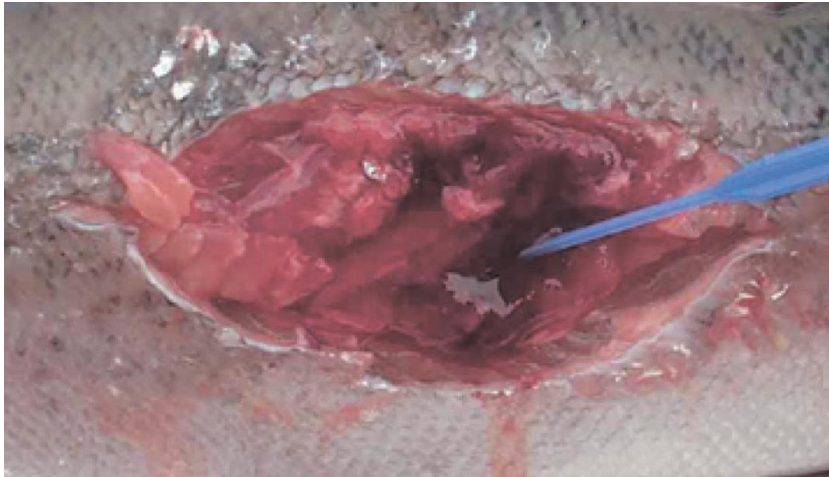
Note: Haemorrhagic lesion on the flank typical of MAS.  
Source: K Ellard

**Figure 5 Atlantic salmon (*Salmo salar*) with blood filled MAS ulcerations**



Note Blood-filled furuncles in MAS are rarely noted, because they rupture easily.  
Source: K Ellard

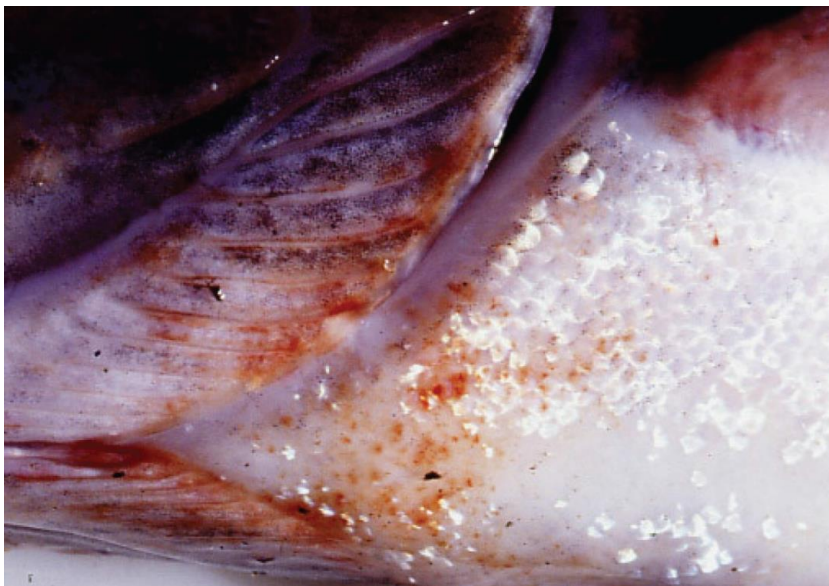
**Figure 6 Atlantic salmon (*Salmo salar*) with MAS ulcer exposed below the surface of the skin**



Note: The MAS lesion extends into the underlying muscle.

Source: K Ellard

**Figure 7 Atlantic salmon (*Salmo salar*) infected with greenback flounder strain of atypical *A. salmonicida* after cohabitation with infected flounder**



Note: Haemorrhagic lesions around the isthmus and branchiostegal membranes.

Source: J Carson

## Signs of disease

Important: Animals with this disease may show one or more of these signs, but the pathogen may still be present in the absence of any signs.

Disease signs at the farm, tank or pond level are:

- lethargic swimming
- abnormal swimming and disorientation
- loss of appetite
- increased mortality.

Gross pathological signs are:

- white raised patches on the skin that progress to ragged-edged red ulcers
- haemorrhages on the skin and fin bases (usually the paired fins)
- fingernail-sized ulcers found anywhere on the fish, most often on the upper side of the lateral line behind the head or at the base of the tail fin
- pale gills with petechial (pinpoint) haemorrhages
- intestinal protrusion through the abdominal wall following severe ulceration
- haemorrhages in muscle and internal organs
- swollen kidneys and spleen.

Microscopic pathological signs are:

- hyperplasia of the gills, which may contain bacterial colonies
- ulcerated areas that show oedema, hyperaemia, leukocyte infiltration and considerable degenerative changes
- hyperaemia and haemorrhage in the spleen and kidneys
- fibroblast-like cells, which may produce granulomas in the dermis, spleen and kidney.

### Disease agent

Atypical strains of the *Aeromonas salmonicida* bacterium within the family *Enterobacteriaceae* differ from the typical strain causing furunculosis in salmonids. Atypical strains affect mainly non-salmonids (wild and cultured, marine and freshwater). Infection with atypical *A. salmonicida* does not necessarily result in the acute mortality and septicaemia that are characteristic of the typical furunculosis strain, but manifests more as external lesions and ulceration, often involving secondary infection. An exception is MAS in Tasmania; in such cases, Atlantic salmon are most commonly affected, and clinical presentation is similar to furunculosis.

There are five subspecies of *A. salmonicida*. *A. salmonicida salmonicida* is known as the typical strain and is the only one to cause furunculosis (listed separately in this guide). The other four subspecies (*achromogenes*, *masoucida*, *smithia* and *pectinolytica*) are referred to as atypical *A. salmonicida* and are recognised worldwide. All except *A. salmonicida pectinolytica* cause disease in fish.

*A. salmonicida* biovar Acheron is a new atypical strain recently described in Australia (Tasmania), causing MAS in Atlantic salmon.

### Host range

Laboratory experiments indicate that all trout and salmon species, as well as many non-salmonids, are potentially susceptible to atypical strains of *A. salmonicida*. For example, Atlantic salmon and striped trumpeter can be infected by cohabitation with infected flounder.

Rainbow trout are relatively resistant to atypical strains.

**Table 1 Species known to be susceptible to atypical strains of *Aeromonas salmonicida***

Common name	Scientific name
Amago salmon <sup>a</sup>	<i>Oncorhynchus rhodurus</i>
American eel <sup>a</sup>	<i>Anguilla rostrata</i>
American plaice	<i>Hippoglossoides platessoides</i>
Arctic char	<i>Salvelinus alpinus</i>
Atlantic cod <sup>a</sup>	<i>Gadus morhua</i>
Atlantic herring <sup>a</sup>	<i>Clupea harengus</i>
Atlantic salmon <sup>a</sup>	<i>Salmo salar</i>
Ayu	<i>Plecoglossus altivelis</i>
Black sea salmon	<i>Salmo labrax</i>
Black rockfish <sup>a</sup>	<i>Sebastes schlegelii</i>
Brook trout <sup>a</sup>	<i>Salvelinus fontinalis</i>
Brown trout <sup>a</sup>	<i>Salmo trutta</i>
Bull trout	<i>Salvelinus confluentus</i>
Chub <sup>a</sup>	<i>Leuciscus cephalus</i>
Chinook salmon	<i>Oncorhynchus tshawytscha</i>
Chum salmon <sup>a</sup>	<i>Oncorhynchus keta</i>
Coho salmon	<i>Oncorhynchus kisutch</i>
Common carp and koi carp <sup>a</sup>	<i>Cyprinus carpio</i>
Common roach <sup>a</sup>	<i>Rutilus rutilus</i>
Crucian carp <sup>a</sup>	<i>Carassius carassius</i>
Cutthroat trout	<i>Oncorhynchus clarkii</i>
Dab <sup>a</sup>	<i>Limanda limanda</i>
Dace <sup>a</sup>	<i>Leuciscus leuciscus</i>
Danube salmon	<i>Hucho hucho</i>
Eels	<i>Anguillidae</i> all species
European eel	<i>Anguilla anguilla</i>
Flounder <sup>a</sup>	<i>Platichthys flesus</i>
Fourbeard rockling <sup>a</sup>	<i>Enchelyopus cimbrius</i>
Freshwater bream <sup>a</sup>	<i>Abramis brama</i>
Gila trout	<i>Oncorhynchus gilae</i>
Golden trout	<i>Oncorhynchus aguabonita</i>
Goldfish <sup>a</sup>	<i>Carassius auratus</i>
Goldsinny <sup>a</sup>	<i>Ctenolabrus rupestris</i>
Grayling <sup>a</sup>	<i>Thymallus thymallus</i>
Great sandeel <sup>a</sup>	<i>Hyperoplus lanceolatus</i>
Greenback flounder <sup>a</sup>	<i>Rhombosolea tapirina</i>
Haddock <sup>a</sup>	<i>Melanogrammus aeglefinus</i>

Infection with *Aeromonas salmonicida*—atypical strains

Common name	Scientific name
Hybrid (rainbow trout × coho salmon)	<i>Oncorhynchus mykiss</i> × <i>O. kisutch</i>
Japanese eel	<i>Anguilla japonica</i>
Japanese flounder <sup>a</sup>	<i>Paralichthys olivaceus</i>
Lake trout	<i>Salvelinus namaycush</i>
Lake whitefish	<i>Coregonus clupeaformis</i>
Lesser sand eel	<i>Ammodytes tobianus</i>
Masu salmon <sup>a</sup>	<i>Oncorhynchus masou</i>
Minnow <sup>a</sup>	<i>Phoxinus phoxinus</i>
Pacific halibut <sup>a</sup>	<i>Hippoglossus stenolepis</i>
Pacific salmon <sup>a</sup>	<i>Oncorhynchus</i> spp.
Pike	<i>Esox lucius</i>
Pink salmon	<i>Oncorhynchus gorbuscha</i>
Plaice <sup>a</sup>	<i>Pleuronectes platessa</i>
Rainbow trout <sup>a</sup>	<i>Oncorhynchus mykiss</i>
Redfin or European perch	<i>Perca fluviatilis</i>
Rudd <sup>a</sup>	<i>Scardinius erythrophthalmus</i>
Sablefish	<i>Anoplopoma fimbria</i>
Salmonids (all presumed susceptible) <sup>a</sup>	<i>Salmonidae</i> all species
Shortfin eel	<i>Anguilla australis</i>
Shotted halibut <sup>a</sup>	<i>Eopsetta grigorjewi</i>
Shubunkin <sup>a</sup>	<i>Carassius</i> sp.
Silver bream <sup>a</sup>	<i>Blicca bjoerkna</i>
Silver perch <sup>a</sup>	<i>Bidyanus bidyanus</i>
Smallmouth bass <sup>a</sup>	<i>Micropterus dolomieu</i>
Sockeye salmon <sup>a</sup>	<i>Oncorhynchus nerka</i>
Splake (lake trout × brook trout)	<i>Salvelinus namaycush</i> × <i>S. fontinalis</i>
Spotted wolfish <sup>a</sup>	<i>Anarhichas minor</i>
Striped trumpeter <sup>a</sup>	<i>Latris lineata</i>
Tomcod <sup>a</sup>	<i>Gadus microgadus</i>
Turbot <sup>a</sup>	<i>Scophthalmus maximus</i>
Viviparous blenny <sup>a</sup>	<i>Zoarces viviparus</i>
Whitefish (Muksun)	<i>Coregonus muksun</i>
Whitefish (Peled)	<i>Coregonus peled</i>
Whitefish	<i>Coregonus</i> spp.
Whitespotted char	<i>Salvelinus leucomaenis</i>
Whiting <sup>a</sup>	<i>Merlangius merlangus</i>
Wrasse <sup>a</sup>	<i>Labrus bergylta</i>
Wrasses	<i>Labridae</i> all species

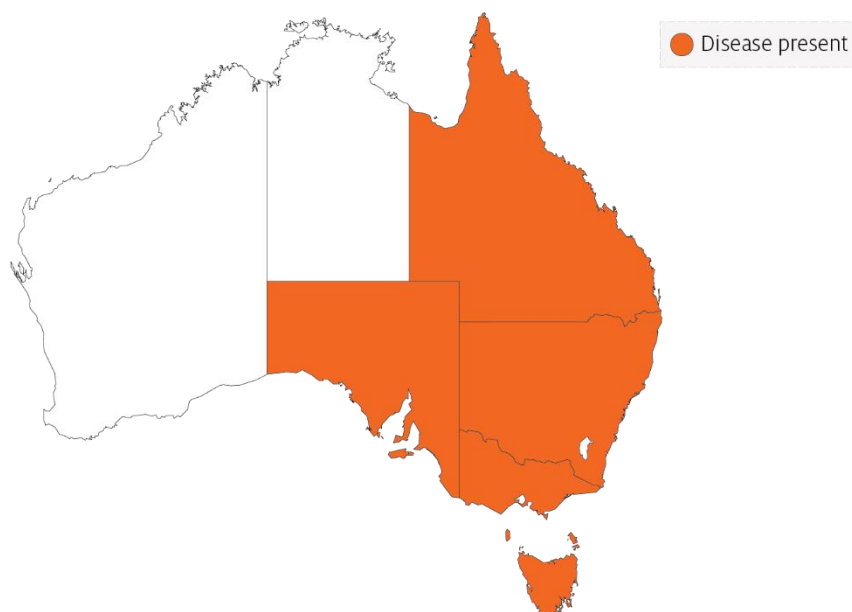
Common name	Scientific name
Yellow bass <sup>a</sup>	<i>Morone mississippiensis</i>

<sup>a</sup> Naturally susceptible. Note: Other species likely to be susceptible.

## Presence in Australia

Atypical *A. salmonicida* has been officially reported from New South Wales, Queensland, South Australia, Victoria (goldfish ulcer disease only) and Tasmania (greenback flounder biovar and Acheron biovar only). Movement controls are in place to prevent the spread of goldfish ulcer disease to Western Australia and Tasmania. The Acheron biovar has been reported only from Tasmania and is limited to an isolated production area.

**Map 1 Presence of atypical strains of *Aeromonas salmonicida*, by jurisdiction**



## Epidemiology

- Transmission occurs horizontally (between fish via the water).
- Susceptibility to the disease increases with damaged mucus and skin, which occurs when fish are handled with nets.
- Outbreaks are expected to occur at water temperatures above 10°C (summer months in southern waters of Australia) and may be precipitated by stress (such as handling, overpopulation and rapid temperature fluctuations).
- Secondary infection with other bacteria often occurs.
- Fish that survive disease outbreaks are recognised as carriers of the disease. Carriers may continue to infect the remaining population without themselves exhibiting signs of infection.
- Diagnosis based on clinical or external signs of disease is difficult because clinical signs vary and skin ulcers are often infected with opportunistic bacteria and fungi. A definitive diagnosis requires laboratory examination.

## Differential diagnosis

The list of [similar diseases](#) in the next section refers only to the diseases covered by this field guide. Gross pathological signs may also be representative of diseases not included in this guide. Do not rely on gross signs to provide a definitive diagnosis. Use them as a tool to help identify the listed diseases that most closely account for the observed signs.

## Similar diseases

Channel catfish virus disease (CCVD), furunculosis, infection with *Aphanomyces invadans* (EUS), koi herpesvirus disease (KHV) and spring viraemia of carp (SVC).

## Sample collection

Only trained personnel should collect samples. Using only gross pathological signs to differentiate between diseases is not reliable, and some aquatic animal disease agents pose a risk to humans. If you are not appropriately trained, phone your state or territory hotline number and report your observations. If you have to collect samples, the agency taking your call will advise you on the appropriate course of action. Local or district fisheries or veterinary authorities may also advise on sampling.

## Emergency disease hotline

See something you think is this disease? Report it. Even if you're not sure.

Call the Emergency Animal Disease Watch Hotline on **1800 675 888**. They will refer you to the right state or territory agency.

## Further reading

Menanteau-Ledouble S, Kumar G, Saleh M, El-Matbouli M 2016, [‘Aeromonas salmonicida’: updates on an old acquaintance](#), *Diseases of Aquatic Organisms*

Whittington RJ, Djordjevic SP, Carson J, Callinan RB 1995, [Restriction endonuclease analysis of atypical ‘Aeromonas salmonicida’ isolates from goldfish ‘Carassius auratus’, silver perch ‘Bidyanus bidyanus’, and greenback flounder ‘Rhombosolea tapirina’ in Australia](#), *Diseases of Aquatic Organisms*

These hyperlinks were correct at the time of publication.

## Contact details

Emergency Animal Disease Watch Hotline 1800 675 888

Email [AAH@agriculture.gov.au](mailto:AAH@agriculture.gov.au)

Website [agriculture.gov.au/pests-diseases-weeds/aquatic](http://agriculture.gov.au/pests-diseases-weeds/aquatic)

© Commonwealth of Australia 2020

This work is copyright. It may be reproduced in whole or in part subject to the inclusion of an acknowledgement of the source and no commercial usage or sale.